

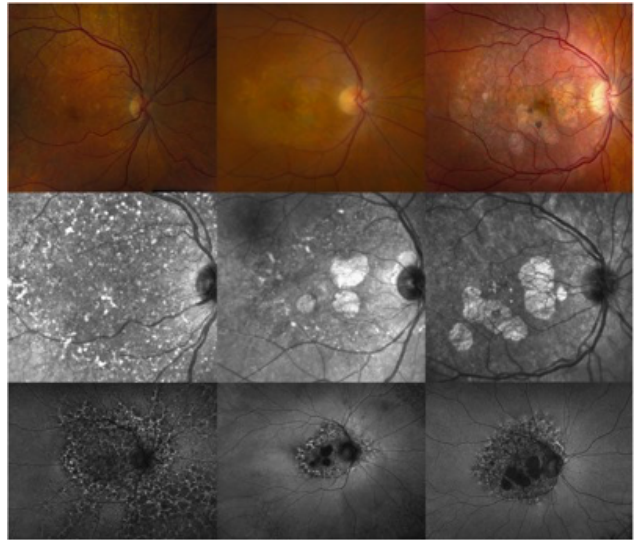
# Elmiron Eye Disease Fact Sheet

If you have or are currently taking pentosan polysulfate PPS (brand name: Elmiron®) and are experiencing eye issues, ophthalmologists across the country have now documented cases of retinal maculopathy (aka retinal injury) in SOME IC patients who have used pentosan for long periods of time. They urge patients who have used or are using pentosan to be screened by ophthalmologists if they are experiencing any unusual eye symptoms (difficulty reading, vision loss, difficulty seeing in lower lights) and to cease pentosan therapy if eye disease is present. This is a brief summary of research to date.

**May 2018 – First Emory Eye Center Case Series - Pigmentary Maculopathy Associated with Chronic Exposure to Pentosan Polysulfate Sodium.** Pearce WA, Chen R, Jain N. Ophthalmology. 2018 May 22.

The Emory Eye Center case series shared the cases of six women with interstitial cystitis who presented to their clinic between May 2015 and October 2017 with pigmentary maculopathy. A maculopathy is condition which affects the center of the retina, an area associated highly sensitive and accurate vision, such as Age-Related Macular Degeneration. Most of these patients had difficulty reading and difficulty in darkness. Two patients experienced a generalized dimming of their vision as the first symptom. Two others had difficulty with near vision. One had paracentral scotomas (vision loss) in part of their eye while the other had metamorphopsia (distorted vision where straight lines become wavy).

All six patients underwent rigorous diagnostic imaging and DNA testing to determine if they had any genes associated with hereditary retinal loss. None had a family history of retinal disease nor the discovery of any pathogenic process. What they did have in common was the use of pentosan (aka Elmiron®) for long periods of time (a median of 186 months.) Five had been treated at a dose of 400mg daily (two of whom reduced their dosage to 200mg daily after 17 years). One patient was treated with a 300mg daily dose. No other medications were used by more than 2 patients in the study.



Examinations of their eyes showed clear changes *“Nearly all eyes (10 eyes of 5 patients) showed subtle parafoveal pigmented deposits at the level of the retinal pigment epithelium (RPE).”* All eyes *“showed subtle vitelliform deposits that increased in number and extended beyond the major arcade of vessels in cases judged to be more severe. Four eyes of 2 patients showed RPE atrophy that was noted to increase in area and encroach on the central fovea over time.”* Findings were *“fairly symmetrical”* between the eyes of each patient. Retinal imaging also found clear diseased regions and/or atrophy though the size varied among patients.

Patient #4 diagnosed at the age of 23. She was taking 400mgs of Pentosan a day. She began showing visual symptoms (difficulty with near vision and difficulty reading) at the age of 30, six years after she was diagnosed. She took Elmiron® for a total of 168 months. She had the most severe damage in the study with deep scotomas of both eyes.

The authors suggest that the retinal cells may be accumulating PPS or a toxic metabolite over time. This is not the first time that eye effects have been discussed. A very early Elmiron study of 2499 patients who

received the drug for up to four years in which vision related adverse events were reported including: optic neuritis, amblyopia and retinal hemorrhage.

They concluded with a plea for education and an urgent need for additional research. *“Clinicians should be aware of this condition because it can be mistaken for other well-known macular disorders, such as pattern dystrophy and age related macular degeneration.”* They strongly encourage drug cessation in affected patients and recommend that any patient with suggestive visual symptoms undergo a comprehensive ophthalmic examination.

- - - - -

**May 2019 – Expanded Emory Data** - Foote, et al. Chronic Exposure to Pentosan Polysulfate Sodium is Associated with Retinal Pigmentary Changes and Vision Loss. AUA 2019 Abstract MP47-03.

At the American Urology Association Annual Meeting (Chicago, IL) in May 2019, the Emory team submitted a new study of ten interstitial cystitis patients who had taken pentosan and experienced macular disease.<sup>(5)</sup> Ranging in age from 38 to 68, the most commonly reported symptoms were difficulty reading (7/10) and difficulty adapting to dim lighting (7/10). Patients had a medium cumulative exposure to pentosan of 2062 grams over time (range 325 to 2883.5) with a median duration of 186 months (range 27 to 240 months). Eye examinations showed symmetric pigmentary changes in the retina. Retinal imaging with FAF and OCT technology demonstrated that the abnormalities were primary in the retinal pigment epithelium. They note that their clinic has seen 156 patients with IC/BPS who did not have any pentosan exposure and these patients showed no pigmentary maculopathy. They conclude that structural changes of the retina are occurring and they are unclear if stopping the medication will alter the course of this retinal disease. They encourage affected patients to discontinue the use of medications and to undergo comprehensive ophthalmic examinations with OCT and FAF imaging.

- - - - -

**October 2019 – First Clinical Population Based Study** - More Evidence Linking Common Bladder Medication to a Vision-threatening Eye Condition. American Academy of Ophthalmology Press Release. October 11, 2019. Accessed 10/16/19

Researchers at Kaiser Permanente (Oakland, CA) found 140 of their patients who had taken Elmiron for a minimum of 5 years, 91 of whom agreed to an eye examination. Twenty two (24%) of these patients showed eye damage and that the damage increased with the quantity of Elmiron taken. The study only assessed patients who were currently using Elmiron. The principle investigator, Dr. Vora, shared by phone that they will also gather information from patients who had stopped the medication and will be expanding their studies.

- - - - -

**November 2019 – First National Multicenter Study Released** - Jain N, et al. Association of macular disease with long-term use of pentosan polysulfate sodium: findings from a US cohort. Br J Ophthalmol. 2019 Nov 6.

Researchers at the Emory Eye Center (Atlanta, GA) share data from a national study of patients. Using data from a large US medical claims database from 2002 to 2016, a total of 3012 and 1604 PPS users were compared with 15,060 and 8,017 matched controls at 5 and 7 years, respectively. The primary outcome measures included (1) any new diagnosis of a hereditary or secondary pigmentary maculopathy (atypical maculopathy outcome), and (2) any new diagnosis of dry age-related macular degeneration (AMD). At 5 years, multivariate analysis showed no significant association ( $p > 0.13$ ) but at 7 years,

pentosan users had significantly increased odds of having the atypical maculopathy+AMD outcome (OR=1.41, 95% CI 1.09 to 1.83, p=0.009).

- - - - -

**November 2019 – First Case Study Suggesting Progression of Eye Disease After Pentosan Is**

**Halted** - Huckfeldt R, et al. Progressive Maculopathy After Discontinuation of Pentosan Polysulfate Sodium. Ophthalmic Surgery, Lasers & Imaging Retina. 2019;50(10):656-659

Dr. Rachel Huckfeldt of the Harvard Medical School Dept. Ophthalmology, published a case study of an IC patient who had used a low dosage of Elmiron (200mg per day) for 18 years who first presented to their clinic at the age of 62 with blurry vision in her left eye and difficulty seeing at night. This had been occurring for a year. Eye studies noted pigmentary changes in the retina that, at that time, left the physicians wondering if the patient had been exposed to a retinotoxic agent. Six years later, the patient returned with worsening vision in both eyes. Examination found significantly more retinal atrophy and damage. The patient returned another two years later at the age of 69 with yet more extensive eye damage noted. Diagnostic testing was negative for any disease causing genes and no other causes could be determined.

After the initial report of eye disease in pentosan was released in 2018, this patients case was found to be consistent with pentosan associated maculopathy. The patient confirmed that she had stopped using Elmiron at the age of 63, prior to her second and third visits to the Harvard clinic. The authors raise a serious concern of progression over time – *“The present case adds a new layer of concern by demonstrating progressive maculopathy continuing for up to 6 years after the cessation of PPS.”* They compare their findings with another medication, hydroxychloroquine (Plaquenil), which has been determined to cause serious eye damage that can progress after that medication is stopped. “This case emphasizes the need for a screening regiment that balances the demands of patients and physicians with the importance of prompt identification of early toxicity.”

For additional information, please visit: [pentosaneyedisease.org](http://pentosaneyedisease.org) or [icnetwork.org](http://icnetwork.org)

A publication of the Interstitial Cystitis Network

[icnetwork.org](http://icnetwork.org)

PO Box 2159

Healdsburg, CA 95448

Toll free: 800-928-7496

Fax: 707-538-9444

E: [icnetwork@mac.com](mailto:icnetwork@mac.com)